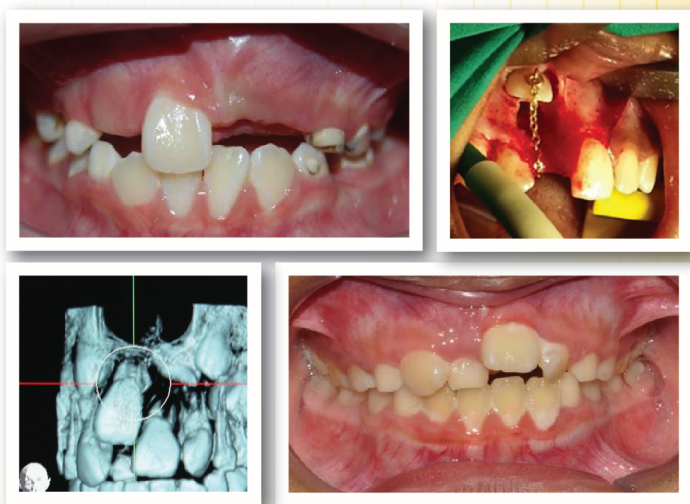



Oral Health Division
Ministry of Health Malaysia

MANAGEMENT OF UNERUPTED MAXILLARY INCISOR

(Second Edition)



November 2015

STATEMENT OF INTENT

These guidelines update and supplant the original guideline developed in 2006 and are based on the best available contemporary evidence. They are intended as a guide for the best clinical practice in the management of unerupted maxillary incisor. However, it must be noted that adherence to these guidelines do not necessarily lead to the best clinical outcome in individual patient care, as every health care provider is responsible for the management of his/her unique patient based on the clinical presentation and management options available locally.

These guidelines were issued in November 2015 and will be reviewed in November 2020 or earlier if important new evidence becomes available.

Published by:

Oral Health Technology Section
Oral Health Division
Ministry of Health Malaysia
Level 5, Block E10, Precinct 1
Federal Government Administrative Centre
62590 Putrajaya, Malaysia

Copyright

The copyright owner of this publication is Oral Health Division (OHD), MOH Malaysia. Content may be reproduced in any number of copies and in any format or medium provided that a copyright acknowledgement to OHD is included and the content is not changed, not sold, nor used to promote or endorse any product or service and not used inappropriately or misleading context.

ISBN: 978-967-0769-48-6

Available on the following websites:

<http://www.moh.gov.my>

<http://www.ohd.gov.my>

<http://www.acadmed.org.my>

Android and iOS platform: MyMaHTAS

TABLES OF CONTENTS		Page
LEVELS OF EVIDENCE AND GRADES OF RECOMMENDATION		i
GUIDELINES DEVELOPMENT AND OBJECTIVES		ii
CLINICAL QUESTIONS, TARGET POPULATION, TARGET GROUP/USER AND HEALTHCARE SETTINGS		iv
GUIDELINES DEVELOPMENT GROUP		v
REVIEW COMMITTEE		vi
ALGORITHM FOR MANAGEMENT OF UNERUPTED MAXILLARY INCISOR		vii
1. INTRODUCTION		1
1.1 Definition		1
1.2 Aetiology		1
1.3 Prevalence		2
2. DIAGNOSIS		3
2.1 Dental and Medical History		3
2.2 Examination and Diagnosis		3
3. PREVENTIVE AND EARLY INTERCEPTIVE MEASURES		5
4. MANAGEMENT		6
4.1 Create and Maintain Sufficient Space		6
4.2 Remove Physical Obstruction		6
4.3 Surgical Treatment for Failed Eruption		8
4.4 Dilacerated Incisor		13
4.5 Ankylosis		14
4.6 Removal of Unerupted Incisor		14
5. CONCLUSIONS		18
6. IMPLEMENTING THE GUIDELINES		18
REFERENCES		20
APPENDIX 1: SEARCH STRATEGY		26
APPENDIX 2: CLINICAL QUESTIONS		27
ACKNOWLEDGEMENTS		28
DISCLOSURE STATEMENT		28
SOURCE OF FUNDING		28

LEVELS OF EVIDENCE

LEVEL	STUDY DESIGN
I	Evidence obtained from at least one properly designed randomised controlled trial
II-1	Evidence obtained from well-designed controlled trials without randomization
II-2	Evidence obtained from well-designed cohort or case-control analytic studies, preferably from more than one centre or research group
II-3	Evidence obtained from multiple time series with or without the intervention. Dramatic results in uncontrolled experiments (such as the results of the introduction of penicillin treatment in the 1940s) could also be regarded as this type of evidence
III	Opinions or respected authorities, based on clinical experience; descriptive studies and case reports; or reports of expert committees

Source: Adapted from U.S./Canadian Preventive Services Task Force

GRADES OF RECOMMENDATION

GRADE	STUDY DESIGN
A	At least one meta-analysis, systematic review or RCT or evidence rated as good or directly applicable to the target population
B	Evidence from well conducted clinical trials, directly applicable to the target population and demonstrating overall consistency of results; or evidence extrapolated from meta-analysis, systematic reviews or RCT
C	Evidence from expert committee reports, or opinions and or clinical experiences of respected authorities; indicates absence of directly applicable clinical studies of good quality

Source: Modified from the Scottish Intercollegiate Guidelines Network (SIGN)

Note: The grades of recommendation relates to the strength of the evidence on which the recommendation is based. It does not reflect the clinical importance of the recommendation.

GUIDELINES DEVELOPMENT AND OBJECTIVES

GUIDELINES DEVELOPMENT

The Development Group for these Clinical Practice Guidelines (CPG) consisted of Orthodontists, Paediatric Dental Specialist, Oral & Maxillofacial Surgeon, Restorative Dental Specialist, Dental Public Health Specialists and Dental Officer. The Review Committee was actively involved in the development process of these guidelines.

The previous edition of the CPG on Management of Unerupted Maxillary Incisor (August 2006) was used as the basis for the development of this CPG. Several improvements have been introduced in this edition. In addition to the general text and photographic updates, new and updated information has been included in the management such as the use of Cone Beam Computed Tomography (CBCT), updates in surgical and restorative components, key messages and recommendations. In addition, clinical audit indicators have also been identified for the purpose of monitoring and evaluating outcomes.

As part of the reviewing process, new evidences were retrieved from publications from year 2006 to June 2015. Literature search was carried out using the following electronic databases: PUBMED/MEDLINE; Cochrane Database of Systemic Reviews (CDSR); ISI Web of Knowledge; Health Technology Assessment (HTA) and full text journal articles via OVID search engine. The reference lists of all relevant articles retrieved were also searched to identify further studies. Free text terms or MeSH terms were used either singly or in combination to retrieve the articles (**Appendix 1**). Only literature in English was retrieved.

There were 14 clinical questions assigned to members of the development group. The group members met a total of seven times throughout the development of this CPG. Literature retrieved were appraised by at least two members and presented in the form of evidence table and discussed during group meetings. All statements and recommendations formulated were agreed upon by both the development group and review committee. This CPG is based largely on scientific evidences and adapted according to local practices. However, where there was a lack of evidence, recommendations were based on consensus of group members. Although, ideally patients'

views and preferences need to be considered in the development of CPGs, in this instance, it was not feasible. Nevertheless, patient information leaflets would be developed to facilitate the dissemination of important information to the public.

The levels of evidence of the literature were graded using the modified version from the United States (U.S) / Canadian Preventive Services Task Force, while the grading of recommendations was based on the modified version of the Scottish Intercollegiate Guidelines Network (SIGN).

The draft guidelines were evaluated by a team of reviewers and were also posted on the Ministry of Health, Malaysia and Academy of Medicine, Malaysia websites for comments and feedbacks. This guideline was presented to the Technical Advisory Committee for CPGs, and finally to the Health Technology Assessment (HTA) and CPG Council, Ministry of Health, Malaysia for approval.

GENERAL OBJECTIVE

To enable clinicians to make informed decisions in the detection and management of unerupted maxillary incisors.

SPECIFIC OBJECTIVES

1. To disseminate and reinforce knowledge on the management of unerupted maxillary incisors among oral healthcare professionals.
2. To provide timely and appropriate management of unerupted maxillary incisors by oral healthcare professionals.

CLINICAL QUESTIONS

The clinical questions addressed by these guidelines are in **Appendix 2**.

TARGET POPULATION

These guidelines will be useful when assessing children from the early mixed dentition stage with signs and symptoms of unerupted maxillary incisors. These exclude patients with cleft lip and palate, association with other syndromes, metabolic disturbances and impacted teeth other than maxillary incisors.

TARGET GROUP/USER

These guidelines are applicable for oral healthcare personnel who are involved in the management of unerupted maxillary incisors.

HEALTHCARE SETTINGS

Primary and specialist oral health care settings at public and private sectors.

GUIDELINES DEVELOPMENT GROUP

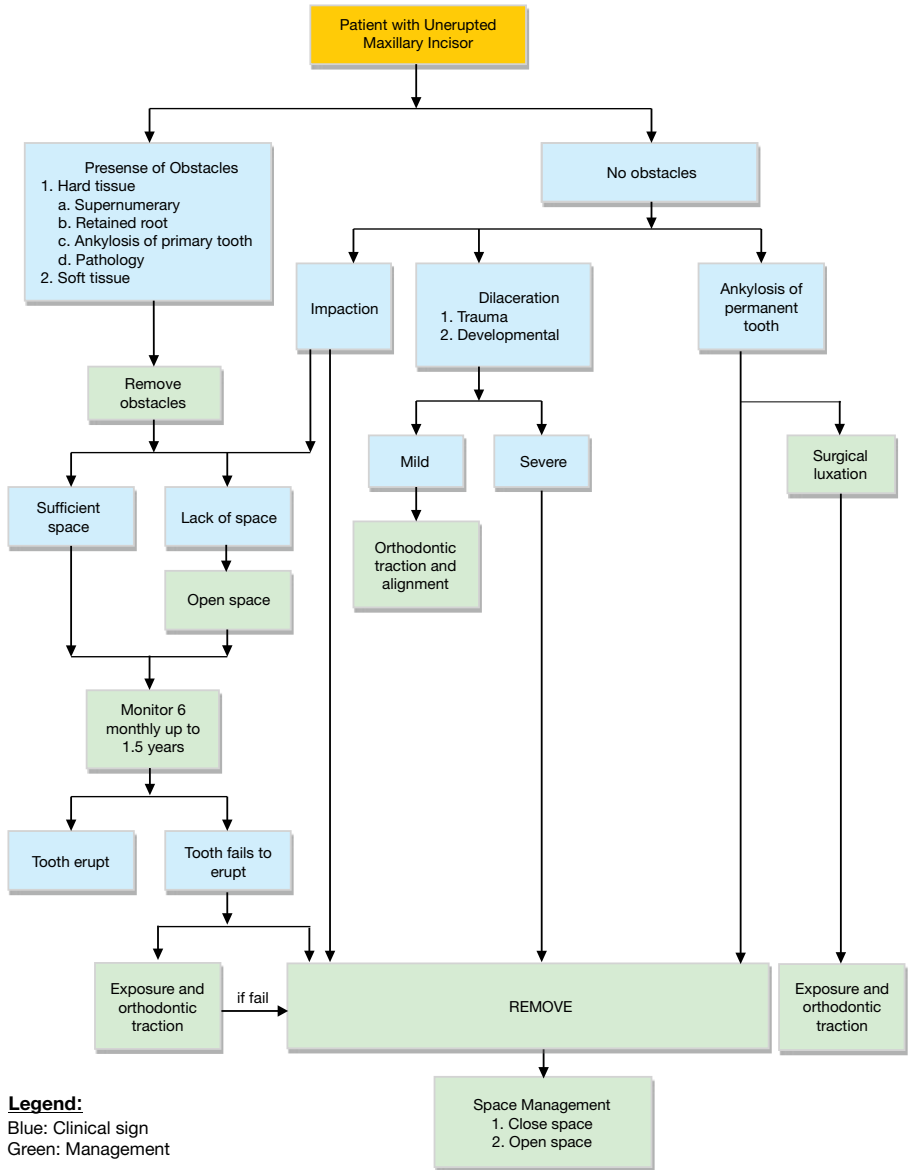
Chairperson	Secretary
Dr. Ahmad Burhanuddin b. Abdullah Consultant Orthodontist Unit Ortodontik Klinik Pergigian Besar Jalan Mahmood 15200 Kota Bharu Kelantan	Dr. Roslili bt. Mat Orthodontist Unit Ortodontik Klinik Pergigian Klinik Kesihatan Bandar Kuala Krai 18000 Kuala Krai Kelantan
Members	
Dr. Rafea'ah bt. Ayat Khan Consultant Orthodontist Unit Ortodontik Klinik Kesihatan Meranti 17000 Pasir Mas Kelantan	Dr. Maria Jirom ak Gere Consultant Orthodontist Unit Ortodontik, Klinik Pergigian Cahaya Suria Aras 3, Bangunan Cahaya Suria Jalan Tun Perak 50050 Kuala Lumpur
Dr. Norhayati bt. Hassan Consultant Oral and Maxillofacial Surgeon Jabatan Bedah Mulut Hospital Putrajaya Precinct 7 62250 Putrajaya	Datin Paduka Dato' Dr. Nooral Zeila bt. Junid Dental Public Health Specialist Unit National Health Financing (NHF) Bahagian Perancangan KKM Aras 3, Blok E6, Parcel E 62590 Putrajaya.
Dr. Arjunan a/l Muthusamy Consultant Orthodontist Unit Ortodontik Klinik Pergigian Ipoh Jalan Panglima Bukit Gantang Wahab 30590 Ipoh, Perak	Dr. Norzakiah bt. Mohamed Zam Zam Consultant Orthodontist Klinik Pergigian Salwa & Juraida No. 92-G, Jalan Wangsa Delima 6 Pusat Bandar Wangsa Maju 53300 Kuala Lumpur
Dr. Raja Zarina bt. Raja Shahardin Paediatric Dental Specialist Jabatan Pergigian Paediatric Institut Paediatric Hospital Kuala Lumpur Jalan Pahang 50586 Kuala Lumpur	Dr. Mah Eng Ching Orthodontist Unit Ortodontik Klinik Pergigian Rawang Jalan Bukit Kelab 48000 Rawang Selangor
Dr. Noorhanizar bt. Mansor Orthodontist Unit Ortodontik Hospital Tuanku Fauziah 01000 Kangar Perlis	Dr. Soh Huey Shyen Orthodontist Unit Ortodontik Klinik Pergigian Taiping Klinik Kesihatan Bandar Taiping Jalan Tupai 34000 Taiping Perak
Dr. Kamarul Hisham b. Kamarudin Restorative Dental Specialist Unit Pergigian Restoratif Klinik Pergigian Cahaya Suria Aras 3, Bangunan Cahaya Suria Jalan Tun Perak 50050 Kuala Lumpur	Dr. Zainab bt. Shamdol Dental Public Health Specialist Bahagian Kesihatan Pergigian KKM Level 5, Block E10, Parcel E 62590 Putrajaya
Dr. Suryati Hartini bt. Mohammed Zini Orthodontist Unit Ortodontik Klinik Kesihatan Jalan Abdul Samad 80100, Johor Bahru Johor	Dr. Sharina bt. Sharudin Orthodontist Unit Ortodontik Klinik Pergigian Klinik Kesihatan Indera Mahkota 25200 Kuantan, Pahang
Dr. Salleh b. Zakaria Dental Public Health Specialist Bahagian Kesihatan Pergigian KKM Level 5, Block E10, Parcel E 62590 Putrajaya	Dr. Noor Ainnilwahida bt. Alias Dental Officer Unit Ortodontik Klinik Kesihatan Jalan Abdul Samad 80100, Johor Bharu Johor

REVIEW COMMITTEE

These guidelines were reviewed by a panel of independent reviewers from both public and private sectors who were invited to comment primarily on the comprehensiveness and accuracy of interpretation of the evidence supporting the recommendations in the guideline. The following internal and external reviewers provided comments and feedbacks on the proposed draft:

INTERNAL REVIEWERS	
<p>Prof. Dr. Rozita Hassan Professor and Consultant Orthodontist Orthodontic Unit School Dental Sciences Universiti Sains Malaysia 16150, Kota Bharu, Kelantan Malaysia</p>	<p>Dr. Noraini Nun Nahar bt. Yunus Senior Consultant of Paediatric Dentistry Jabatan Pergigian Paediatric Institut Paediatric Hospital Kuala Lumpur Jalan Pahang 50586 Kuala Lumpur</p>
<p>Dr. Wan Nurazreena binti Wan Hassan Senior Lecturer and Orthodontist Department of Paediatric Dentistry and Orthodontics Faculty of Dentistry University of Malaya 50603 Kuala Lumpur</p>	<p>Datin Dr. Sorayah bt. Sidek Consultant Periodontist Klinik Pergigian Klinik Kesihatan Presint 18 Jalan P18C2, Presint 18 62602 Putrajaya</p>
<p>Dato' Dr. Rusdi b. Abdul Raman Consultant Oral and Maxillofacial Surgeon Hospital Raja Perempuan Zainab II 15000 Kota Bharu Kelantan</p>	<p>Dr. Rohani b. Mahmood Restorative Dental Specialist Klinik Pergigian Klinik Kesihatan Presint 18 Jalan P18C2, Presint 18 62602 Putrajaya</p>
EXTERNAL REVIEWERS	
<p>Prof. Dr. Stephen Chadwick Senior Consultant, Visiting Professor and Board Member of FDSRCS of England School of Dentistry The University of Manchester Higher Cambridge Street Manchester M15 6FH</p>	<p>Col. Dr. Shalene Kereshanan President Malaysian Association of Orthodontists 21-3A, Tingkat 2, Blok L Jalan PJU 1/3C Sunway Mas Commercial Centre 47301 Petaling Jaya Selangor</p>

Algorithm for Management of Unerupted Maxillary Incisor



Legend:

Blue: Clinical sign
Green: Management

1. INTRODUCTION

Unerupted or clinically missing maxillary incisors can have a major impact on dental and facial aesthetics of an individual. As missing upper incisors are regarded as unattractive, this may have an effect on the self-esteem and social well-being of the individual. Some speech difficulties associated with missing upper incisors have been reported.^{1, level III} Thus, it is important to detect and manage the problem as early as possible to achieve a functioning dentition and a pleasing appearance. Early diagnosis is essential for a successful outcome and reduces the necessity for appliance therapy in some cases.

1.1 Definition

The maxillary incisor is considered unerupted when:

- a) there is no history of previous extraction,
- b) eruption of contralateral incisor has occurred 6 months earlier^{2-4, level III} or if both central incisors are unerupted and the lower incisors have erupted more than one year previously, or^{4, level III}
- c) there is deviation from the normal sequence of eruption such as lateral incisors erupt before the central incisors.^{3-4, level III}

1.2 Aetiology

The possible causes of maxillary incisors failing to erupt include:

- a) Congenital
Unerupted incisors may be considered part of a spectrum of inheritable dental anomalies.^{5, level III}
 - Presence of supernumerary tooth (**Figure 1**) is a common cause of failure of eruption.^{6, level II-3} 42% to 62% of midline supernumeraries are associated with unerupted permanent incisors.^{7-10, level II-3} Maxillary incisor that fails to erupt due to the presence of a supernumerary tooth has a better prognosis than those with other aetiology.^{6, level II-3}
 - Ectopic development such as severe malposition and/or impaction against another tooth may inhibit the permanent incisor from erupting.^{11, level III}
 - Other pathologies such as cysts and odontomes may also prevent eruption of the permanent incisor.^{6, level II-3; 12, level III}

- Generalised delay or failure of eruption are associated with certain conditions such as cleidocranial dysostosis, gingival fibromatosis and some clefts lip and palate. ^{13, level III}

b) Environmental

- Retained deciduous teeth. ^{9, level II-3; 14, level III}
- Dilaceration of the permanent maxillary incisor resulted from trauma to the deciduous predecessor (22%) and the remaining were probably developmental in origin (71%). ^{15, level II-3}
- Ankylosis, where the root of the maxillary incisor becomes fused to the alveolar bone. ^{16, level III}
- Dense mucoperiosteum can occur during development or due to the formation of scar tissue following surgery. ^{16, level III}
- Thickened or enlarged follicles around the unerupted incisor crown. ^{17, level II-1}

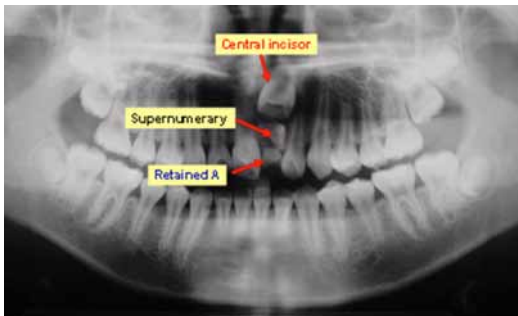


Figure 1:
Example of an orthopantomogram (OPG) showing an unerupted maxillary left central incisor obstructed by a supernumerary tooth and a retained deciduous tooth

1.3 Prevalence

The prevalence of unerupted maxillary incisors in the 5-12 year age group has been reported as 0.13%. ^{18, level II-3} In a referred population to regional hospitals the prevalence has been estimated at 2.6%. ^{8, level II-2} Unerupted incisors are more common in males than females with a ratio of 2.7:1. ^{5, level III} Almost half (47%) of all unerupted maxillary incisors are due to supernumeraries. ^{6, level II-3} The mesiodont variety has more eruptive disturbances compared to the palatodont. ^{8, level II-2}

2. DIAGNOSIS

2.1 Dental and Medical History

A detailed dental and medical history should be obtained to determine possible aetiology, which may cause delayed eruption. Medical and dental history should include:

- Family medical history (any syndromic tendencies)
- History of trauma and extraction

2.2 Examination and Diagnosis

Early clinical examination with radiographic investigation at age of 6-8 years can detect presence of unerupted maxillary incisors,^{3, level III} which would allow early interception and monitoring and thus may improve treatment outcome.

2.2.1 Clinical Examination

An intra-oral examination should be conducted for the presence of the following:

- Retained deciduous teeth (**Figure 2**)
- Buccal or palatal swelling
- Availability of space for the incisor (about 9 mm for a central incisor and about 7 mm for lateral incisors)^{19, level III}

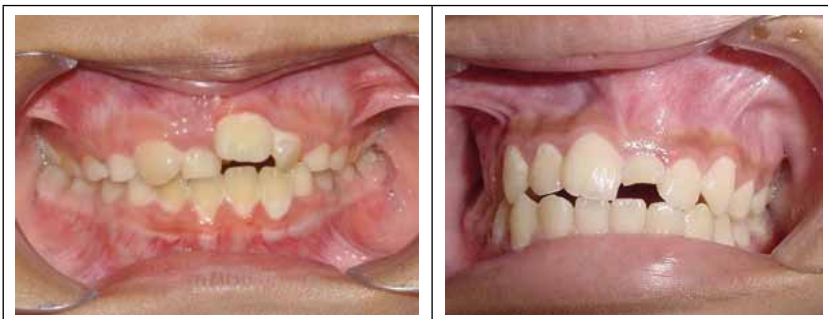

Figure 2: Unerupted maxillary right and left central incisors (Photo credit: Roslili Mat)

2.2.2 Radiographic Investigations

The following radiographs may aid in the diagnosis and management:

- An anterior occlusal radiograph for general assessment purposes ^{20, level III}
- Two periapical radiographs should be taken using the parallax technique for detailed assessment of the position, root and crown morphology. ^{21-22, level III} It has been shown that the use of horizontal parallax technique is better than vertical parallax in localization of impacted canines ^{23, level II-3}
- If an anterior occlusal and a panoramic radiograph are already available, the vertical parallax can also be used for assessment ^{20, level III}

2.2.3 Cone-Beam Computed Tomography (CBCT)

In recent years CBCT has been introduced as a technique for imaging of dental and maxillofacial structures. ^{24, level III} CBCT is a medical image acquisition technique based on a cone-shaped X-ray beam centred on a two-dimensional (2D) detector. The source-detector system performs one rotation around the object producing a series of 2D images. The images are reconstructed in a three-dimensional (3D) data set using a modification of the original cone-beam algorithm. ^{25, level III}

CBCT imaging provides orthodontists with an excellent tool to improve diagnosis, treatment planning and outcome assessment in appropriate malocclusion cases. ^{26, level III} Studies have shown that CBCT is more sensitive than conventional radiography for both impacted teeth localization and identification of root resorption of adjacent teeth. ^{27, level II-3} The comprehensive images in three planes provided by CBCT can assist surgeons in choosing the appropriate surgical approach, identifying the tooth that should be extracted, and reducing the amount of surgical trauma on the adjacent hard and soft tissues. ^{28, level III}

Exposure levels of the CBCT systems falls between medical CT and conventional radiography. Selection of the most appropriate imaging modality should be decided in view of the delivered doses, required image quality and information and the clinical circumstances. ^{29-30, level III} CBCT should only be used when the clinical question cannot be answered by conventional radiography and the field of view should be limited to the region of interest. ^{31, level III} Example of CBCT images showing an unerupted maxillary left central incisor as in **Figure 3**.

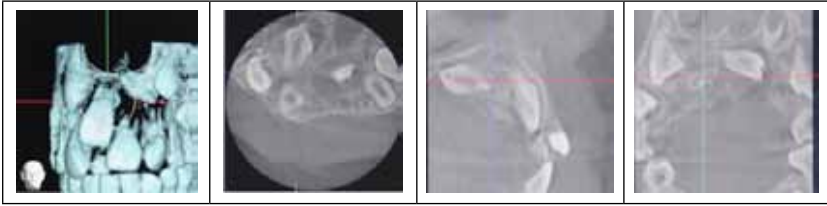


Figure 3: A CBCT images showing unerupted maxillary left central incisor (Photo credit: Raja Zarina Raja Shahardin)

- Clinical examination and conventional radiographs are the first line in diagnosing unerupted maxillary incisor.
- CBCT can be used in selected cases in which conventional radiography cannot provide sufficient diagnostic information.

3. PREVENTIVE AND EARLY INTERCEPTIVE MEASURES

Most eruptive anomalies can be prevented with proper timing and early diagnosis at ages 6 to 8 years. ^{3, level III; 32, level II-1} The earlier the removal of the causative factor the better is the prognosis. Therefore, it is recommended that teeth that have not erupted 6 months after normal eruption time should be investigated radiographically. ^{33, level II-3}

Any retained deciduous teeth should be removed if the incisor is close to eruption. ^{4, level III} When space is created for eruption, 75% will erupt spontaneously; out of which 55% will align spontaneously. ^{17, level II-1; 33, level II-3}

Obstructions should be removed as early as possible when sufficient space is available for eruption. The earlier the obstruction is removed, the better the prognosis. ^{34, level III} Where the obstruction is caused by the presence of supernumerary teeth, 54% to 74% will erupt spontaneously within 16 months provided sufficient space is available. ^{36, level II-2; 35, 37, level II-3} Removal of the supernumerary will aid in the path of eruption of permanent tooth. ^{38, level II-3}

Recommendation 1:

Early removal of obstructions and creation of space would facilitate spontaneous eruption of unerupted tooth. **(Grade B)**

4. MANAGEMENT

4.1 Create and Maintain Sufficient Space

The availability of space to accommodate the impacted tooth is prerequisite in the management of unerupted incisors. ^{17, level II-1; 39, 40, level III; 35, 41, level II-3}

Adequate space (at least 9 mm for the central incisor and 7 mm for the lateral incisor) should be created prior to any surgical intervention to enhance spontaneous eruption. Almost half of the impacted incisors erupt spontaneously following the removal of obstruction and creation of space. ^{42, level II-3; 43, level II-1}

Maintenance of the space throughout the treatment is crucial to prevent lost of space which can lead to secondary inhibition of spontaneous eruption of the impacted tooth. ^{38, level II-3}

Recommendation 2:

Sufficient arch space has to be created and maintained for the eruption of permanent maxillary incisor. **(Grade B)**

4.2 Remove Physical Obstruction

- **Retained deciduous tooth**

The retained deciduous tooth should be extracted to allow the permanent incisor to erupt. Approximately 0.2% of retained deciduous roots and 0.3% of retained deciduous teeth have been found to obstruct eruption of permanent incisors. ^{9, level II-3}

- **Soft tissue**

Thickened or enlarged follicles around the unerupted incisor crown and hyperplastic/scar tissue are potential barriers to eruption.^{17, level II-1} The soft tissue barrier should be treated with an uncovering procedure that includes crown exposure.^{44, level III} Removal of the fibrous tissue overlying the crown will result in rapid eruption in most cases.^{17, level II-1}

- **Supernumerary/odontome**

The presence of a supernumerary tooth or odontome does not necessarily cause delayed eruption of incisors.^{8, 46, level II-3; 40, level III; 45, level II-2} However, observation with regular radiographic controls is advisable to detect any pathological changes.^{9, 10, level II-3; 45, level II-2}

- **Cyst / pathological lesion**

The incidence rate of dentigerous cyst affecting the permanent incisor is approximately 1.5%.^{47, level III} A conservative approach is preferred in the management of unerupted incisor associated with cyst in children in order to preserve the tooth. As children have greater bone regenerative potential and tooth with incomplete root development maintain the eruptive strength, marsupialization or decompression technique is the treatment of choice.^{48, level III} The cyst cavity will be filled with new bone while the tooth is allowed to erupt spontaneously or orthodontically brought into position.^{49, level III} Apart from being an atraumatic and less invasive procedure, marsupialization can also prevent psychological and mental trauma in children.^{50, level III}

About 50% to 78% of impacted maxillary incisors will erupt spontaneously following removal of the supernumerary and full eruption occurs within 1.5 – 3.0 years.^{35, 37-38, 41, 46, level II-3; 36, level II-2; 40, 51, level III}

The earlier the removal of the causative factors, the better the prognosis for alignment of the incisor, although the optimal time for surgical removal of supernumerary teeth is controversial.^{33, 38, 46, level II-3; 40, 52, level III}

Almost three-quarters of incisors with incomplete root development erupt spontaneously after removal of the associated supernumerary teeth. More than half of the incisors with complete root development required further operation. These incisors should be exposed with or without bonding at the time of removal of the supernumerary teeth.

41, level II-3

Spontaneous eruption of impacted tooth occurred in almost half of the cases after removal of the supernumerary of which the majority erupted within 18 months.

4.3 Surgical Treatment for Failed Eruption

After removal of physical obstructions, the unerupted incisor should be observed for about 12-18 months for spontaneous eruption.

4, level III If the incisor fails to erupt with no obvious obstruction the following surgical intervention can be considered:

- a) Exposure with/without orthodontic traction
- b) Removal of the impacted incisor

It was found that 87% immature roots were present in children less than 10 years old compared to only 27% in those above 11 years old. About 72% of unerupted incisors with immature roots erupted spontaneously following extraction of supernumerary while 63% of those with mature roots required further surgical treatment. 41, level II-3 Therefore, it may be prudent to expose the unerupted incisor with mature root, with/without bonding and orthodontic traction of the tooth at the time of extraction of the supernumerary. 41, level II-3

Attachment of bracket and gold chain (**Figure 4**) placed at same time as surgical procedure to remove the obstruction may benefit the unerupted maxillary incisors with near complete apical formation.

7, 41, level II-3

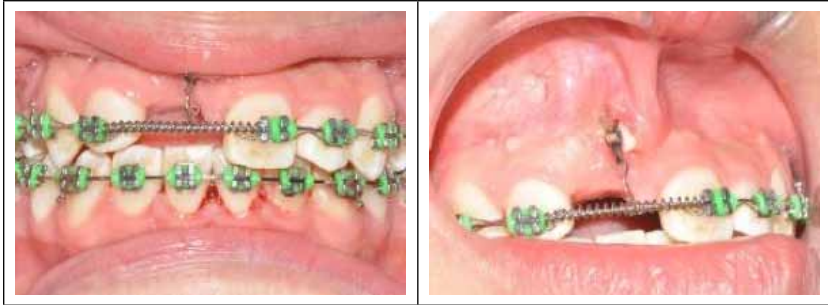

Figure 4: Orthodontic traction with gold chain (Photo credit: Roslili Mat)

However, maturity of the impacted tooth and the developmental stage of the incisors were found not to affect the treatment time when surgical removal of any obstruction and traction initiation in combination with orthodontic space creation and final alignment were practised.^{53, level II-2}

Surgical exposure should also be done if there is lack of eruptive movement due to either an enlarged follicle or scar tissue acting as a barrier.^{17, level II-1} The exposure should aim to provide a functional width of attached gingiva on the labial surface in order to prevent the muscles of the face from detaching the marginal periodontal tissue from the tooth, causing marginal bone loss and gingival recession.^{54, level II-3}

4.3.1 Surgical Techniques

There are various surgical techniques to uncover the unerupted teeth. Two basic approaches are open and closed eruption techniques.

4.3.1.1 Open Eruption Technique

The impacted tooth is left exposed to the oral environment following surgery and surrounded by the incised palatal or labial mucosa. An attachment may be placed during or after the procedure. This technique is termed open eruption technique or exposure and can be performed in two ways:

a) The window technique

This direct technique involves removal of the overlying mucosa and the exposed tooth will have a non-keratinized labial gingival mucosa.

- b) The apically repositioned flap
The procedure involves apically repositioning the raised flap that incorporates attached gingiva overlying the impacted tooth and is expected to provide adequate width of attached gingiva.

4.3.1.2 Closed Eruption Technique

The closed eruption technique has been favoured by many clinicians who claimed that the aesthetic and periodontal outcome is far more superior when compared with the apically positioned flap. ^{55, level II-2}

With this method, a labial or palatal flap is raised and an attachment with gold chain or a bracket/eyelet with ligature wire is bonded to the enamel surface of the tooth using acid-etch technique, preferably with a light cured adhesive, before the flap is replaced (**Figure 5**). Orthodontic traction is then applied. ^{56-59, level III}

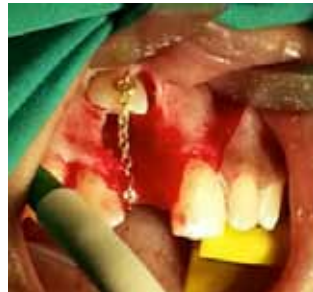

Figure 5:
Exposure and placement of orthodontic attachment using closed technique
(Photo credit: Norhayati Hassan)

4.3.2 Open versus Closed Eruption Technique

There are a few criteria to evaluate when considering the best method for uncovering unerupted tooth. ^{60-61, level III}

- **Labio-palatal Position of the Unerupted Tooth**
For labially positioned tooth any technique is possible. However, if the unerupted tooth is in the centre of the alveolus, it may be difficult to approach by the two open eruption techniques (window and apically position flap). A simple window technique may be preferred if the impacted tooth is low down in the alveolus and bucco lingually close to its place in the arch.

For palatally positioned tooth where there is presence of thick palatal mucosa tissue the window technique usually requires

placement of a periodontal pack to prevent regrowth of tissue over the exposed tooth.

- **Vertical position of the unerupted tooth relative to the mucogingival junction**

If the crown of the unerupted tooth is positioned coronal to mucogingival junction any one of the three techniques can be used to uncover the tooth. If it is positioned apical to the mucogingival junction, the window technique may not be appropriate and the apically position technique is appropriate. To uncover the tooth that is significantly apical to the mucogingival junction, a close eruption technique is preferred.

- **The amount of gingiva in the area of the unerupted tooth**

In the presence of insufficient gingiva in the area of the unerupted tooth, an apically positioned flap is preferred. 2 - 3 mm of attached gingiva over the crown of the tooth allows any of the three technique to be used.

- **The mesio-distal position of the crown of the tooth**

If the central incisor is positioned over the root of the lateral incisor it would be difficult to move the tooth through the alveolus, unless completely exposed with apically positioned flap. The close eruption or excisional uncovering generally is not recommended.

4.3.3 Effect on Eruption

A study showed that to facilitate eruption, 41% of the unerupted incisor teeth required surgical exposure while 59% required surgical exposure with bonding of an orthodontic attachment for traction. Hence, an attachment placed at the same time as surgical procedure to remove the supernumerary may benefit the non-erupted maxillary incisors with near complete apical root formation. This may prevent the patient from having to undergo a second surgical procedure. ^{7, level II-3; 39, level III}

There may be a risk that the tooth may still fail to erupt following surgical exposure. A study on impacted canine shows that the rate of ankylosis following open surgical exposure technique was 3.5% and 14.5% in the closed technique.^{62, level II-1} However, there is no such study available involving unerupted maxillary incisors.

4.3.4 Effect on Periodontal Tissue

The long term unfavourable aesthetic and periodontal effects on the treated unerupted incisors has been noted following open eruption technique. The technique has been associated with significant increase in crown length, reduction in the width of the attached gingiva, increased in pocket depth, abnormal gingival contour and gingival scarring. ^{55, level II-2; 63, level II-1} The apically positioned flap is a valid and effective technique that facilitates long term maintenance of the periodontal health. However, aesthetics may be compromised by the visible scar and longer clinical crown. ^{63, level II-1} A modified apically repositioned flap has been used in the treatment of unerupted maxillary central incisors by incorporation of palatal mucosa resulting in successful establishment of an attached gingival margin. ^{65, level III} In addition, the close eruption technique showed less width of attached gingiva on the distal surface and increased probing bone level. ^{55, level II-2} Both open and closed exposure methods have their place and will produce acceptable outcomes when appropriately selected. ^{61, level III}

A well-planned multidisciplinary approach will ensure a successful treatment outcome.

Recommendation 3:

Placement of orthodontic attachment at the same time as the surgical exposure may prevent a second surgical procedure.
(Grade B)

4.4 Dilacerated Incisor

In early developmental stages, the permanent tooth germ of the maxillary incisor is situated palatally and superiorly to the apex of the primary incisor. The tooth germ gradually changes direction in a labial direction with its crown moving closer to the resorbing primary root.

Due to the close relationship between the permanent tooth germ and the apex of the primary incisor, it is believed that an acute trauma to the primary predecessor can cause dilaceration of the developing root along the vertical axis of the permanent successor (**Figure 6**). Clinically, dilaceration can be felt by palpating high in the labial sulcus or in the hard palate.^{66, level III}

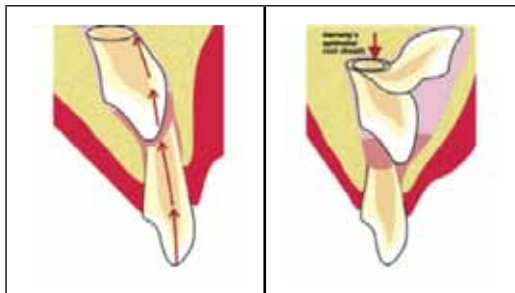


Figure 6: Schematic diagram of a dilaceration mechanism

Source: Reproduced with permission from Nikolaos Topouzelis, Phoebus Tsaousoglou, Vasiliki Pisoka, Lampros Zouloumis. Dilaceration of maxillary central incisor: a literature review. *Dental Traumatology* 2010; 26: 427–433.

It has been reported that dilacerations of central incisors following trauma to deciduous predecessors usually require extraction. Congenital displacement or idiopathic aetiology usually has more favourable prognosis for orthodontic alignment.^{67-68, level III} The dilacerated incisor may be brought into the line of the arch depending on the degree of deformity.^{68-70, level III} Such tooth may require root filling and/ or apicectomy.

The treatment of dilacerated tooth should commence early, to provide the opportunity for the non-calcified root to change direction and develop a proper spatial relationship with the already calcified formed crown.^{71, level III} Following surgical exposure with the closed-eruption

technique and appropriate orthodontic traction, the tooth may be aligned into the dental arch and the crown-root angulation can be improved and continue developing. To this end, an inter-disciplinary approach is considered necessary to ensure an optimal outcome.

72, level III

If the dilaceration is severe or the incisor is ankylosed with poor prognosis for alignment, the permanent incisor may be removed. In this case the options of space opening and maintenance or space closure have to be decided carefully prior to extraction. Adequate space should be maintained initially with a fixed or removable prosthesis.

73-75, level III

Treatment should start as early as possible, to minimize the severity of a developing dilacerated tooth.

4.5 Ankylosis

Ankylosis can occur in both deciduous and permanent dentition. Trauma in deciduous incisors resulted in 4.9% of the deciduous incisors to be ankylosed.

76, level II-2

This can cause obstruction to the erupting permanent incisor. In ankylosed primary incisors, extraction of the ankylosed tooth and observation for the eruption of its successor, space creation and/or maintenance is advised. Space maintenance can be carried out by making a series of transitional prosthesis.

77-78, level III

In ankylosed permanent tooth, extraction and prosthetic replacement or surgical luxation with forced eruption of the tooth is advised.

49, 78-79, level III

Distraction osteogenesis of an ankylosed permanent maxillary incisor with subsequent orthodontic adjustment has been reported.

78, level III

4.6 Removal of Unerupted Incisor

If an unerupted permanent incisor with a poor prognosis has to be removed, the options are either to open or close the missing incisor space.

4.6.1 Open Space or Close Space Decision

Generalized spacing in the arch indicates that space opening for a subsequent prosthesis will usually be more appropriate than space

closure. Conversely where crowding is present, space closure is preferable. ^{80, level III} In the deciduous or mixed dentition stage, the retained deciduous tooth should be maintained as long as possible to preserve alveolar bone for a potential implant-retained crown. Composite resin can be added to maintain the mesial, distal and incisal dimensions. However, if extraction of the contralateral deciduous tooth is indicated, both deciduous maxillary should ideally be removed to maintain arch symmetry. This also allows mesial eruption of canines into the incisor positions for future space closure.

4.6.2 Close Space with Orthodontic Treatment

In the case of space closure, the adjacent teeth should be approximated and modified to mimic the missing incisor. This technique has an advantage of removing the need for prosthetic replacements.

^{73-74, 81-82, level III}

Restorative reshaping or 'remorphologization' can be carried out before, during or after the orthodontic treatment. Enamel reduction, composite build-up, veneer placement or combinations based on pre-treatment canine shape will be required in order to achieve optimal aesthetics. Darker shade of canines was found to be the major cause of dissatisfaction. ^{83-84, level III} Any colour difference in composite build-up can be reduced using vital bleaching. Removal of excessive anterior guidance at palatal canine should be considered with due attention given to the large palatal pulp horn in children. ^{80, level III}

In a retrospective study, 93% of space closure group were very or moderately satisfied with appearance compared with 65% in the prosthetic replacement group. ^{84, level III} The former group was also significantly more satisfied with the appearance of their teeth compared with their friends, than subjects in the latter group. Altogether, 40% were dissatisfied with the symmetry of the upper incisor segment due to differences in shape and colour of the teeth next to the central incisor and worse result noted in unilaterally missing incisor. No implants however were used as prosthetic replacements.

4.6.3 Restore Space with Autotransplantation

Autotransplantation of developing premolars into the extracted incisor region provides an alternative approach in some clinical situations (especially in young patients and presence of crowding in the dental arch).

The best outcome is obtained when the donor tooth root development has reached one-half to three-quarters of the final root length, although a favourable outcome has also been reported in tooth with complete root development. ^{85-86, level II-2}

Autotransplantation has the advantages of inducing bone formation and reestablishment of normal alveolar process. This treatment option may be considered as a temporary measure in young patient in order to maintain the volume of alveolar bone ridge. ^{87, level III; 88, level II-2}

Impairment in root growth, pulp obliteration and root resorption are the common complications that clinicians should be aware of. ^{89-90, level II-1}

4.6.4 Restore Space with Dental Prosthesis

The space may be restored with a fixed or removable prosthesis. Modifications to adjacent teeth and attention to the marginal gingiva will enhance aesthetics ^{74-75, 82, 91, Level III}

a) Adhesive bridges

'Maryland' type bridges which were reported with 60% ten-year survival rate, are minimally invasive. They are therefore popular for intermediate and definitive restorations for missing lateral incisors. However, lack of crown height can result in insufficient surface for bonding, lack of room for framework connectors, as well as metal 'show-through' at the incisal one-third of abutments. As a result, surgical crown lengthening may be necessary. ^{80, level III} Patient should be aware that, when an adhesive bridge debonds following orthodontic treatment, space loss can be surprisingly rapid. ^{80, level III}

b) Conventional full-preparation bridgework

This is usually reserved for patients where the abutment teeth are heavily restored or when they are indicated for crown coverage.

c) Removable chrome partial denture

This offers an affordable interim or even reversible semi-definitive replacement whilst waiting for definitive restorative work. Whilst the acrylic component may aesthetically and functionally replace and/or mask supporting tissue defect, the rigid alloy framework may offer stabilisation of the arch following orthodontic treatment and thus, may allow re-establishment of occlusal stability. ^{92, level III}

d) Restore space with implant

An implant (**Figure 7**) may be considered for adolescents provided that dental and skeletal maturation is complete or almost complete.^{93, level II-2} Good survival rates, aesthetics, safety, efficacy and highly predictable results with different implant systems provided strict protocols and case selection is adhered to.^{94, level III; 95-96, level II-2} Infraocclusion of the implant-supported crown may occur due to slight continuous eruption of the adjacent teeth post-adolescent. This is especially so in unilateral maxillary lateral incisor implants. Bilateral implants have less aesthetic problems.^{9, level II-3} Implant treatment can be complicated by a lack of interocclusal space for the implant superstructure (usually at least 7mm). Inadequate clearance may necessitate soft or hard crestal tissue to be removed, although ideally the opposing teeth should be orthodontically intruded beforehand.^{80, level III} The coronal mesio-distal restorative space required is determined from the diagnostic wax up or from the presence of contralateral tooth or space. These factors should be taken into account at the treatment planning stage.

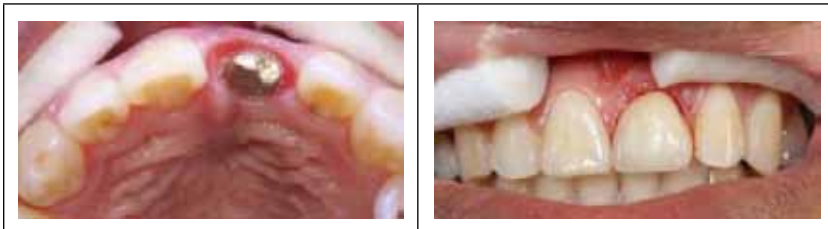

Figure 7: Implant abutment and crown of missing maxillary left central incisor (Photo credit: Kamarul Hisham Kamarudin)

- Restorative treatment options depends on either to open or close the missing incisor space.
- Retained deciduous tooth should preferably be maintained to preserve alveolar bone until definitive restorative work is decided.

5. CONCLUSION

Unerupted maxillary incisors should be identified early and managed accordingly based on a comprehensive clinical examination and radiographic investigation. Depending on the position and prognosis of the tooth, appropriate treatment plan with multidisciplinary involvement should be carried out.

Successful treatment outcome depends on early detection and multidisciplinary approach.

6. IMPLEMENTING THE GUIDELINES

These guidelines provide evidence-based recommendations for the management of unerupted maxillary incisors in Malaysia.

Limiting Factors in Implementation

Potential limiting factors in the implementation of CPG are as follows:

- a) Poor understanding/limited knowledge on unerupted maxillary incisor among patients/caregivers and healthcare providers
- b) Insufficient resources, lack of expertise in the management of unerupted maxillary incisor and diagnostic tools
- c) Variation in treatment practice and preferences
- d) Lack of coordinated referral and follow-up system

Methods to Facilitate Implementation

It is hoped that implementation of the CPG recommendations would be effective through:

- a) dissemination of the CPG to healthcare providers
- b) regular update for healthcare providers

Potential Resource Implications

There should be a strong commitment to:

- a) ensure widespread distribution of the CPG to healthcare providers
- b) initiate training of healthcare providers ensuring information is up-to-date
- c) allocate adequate funding to ensure the effective implementation of the CPG recommendations

Proposed Clinical Audit Indicator for Quality Management

To assist in the implementation of the CPG, the following are proposed as clinical audit indicators for quality management:

$$\text{Success* rate of eruption of unerupted maxillary incisor} = \frac{\text{No. of cases with successful eruption}}{\text{No. of cases with unerupted maxillary incisor treated}} \times 100$$

- * Success is defined as eruption of unerupted maxillary incisor into functional occlusion. This includes spontaneous eruption and orthodontic interventions.

REFERENCES

1. Snow K. Articulatory Proficiency in Relation to Certain Dental Abnormalities. *Journal of Speech and Hearing Disorders*, 1961; 26: 209 – 212.
2. Scheiner MA, Sampson WJ. Supernumerary Teeth: A Review of the Literature and Four Case Reports. *Australian Dental Journal*, 1997; 42(3):160-165.
3. Ibricevic H, Al-Mesad S, Mustagrudic D, Al-Zoherjy Supernumerary Teeth Causing Impaction of Permanent Maxillary Incisors: Consideration of Treatment. *Journal of Clinical Paediatric Dentistry*, 2003; 27(4):327-332.
4. Yaqoob O, O'Neill J, Gregg T, Noar J, Cobourne M and Morris D. Management of Unerupted Maxillary Incisors. *Royal College of Surgeons England Publication*, 2010.
5. Bartolo A, Camillery A, Camillery S. Unerupted Incisors - Characteristic Features and Associated Anomalies. *European Journal of Orthodontics*, 2010; 32: 297 – 301.
6. Betts A, Camilleri GE. A Review of 47 Cases of Unerupted Maxillary Incisors. *Int J Paediatr Dent*, 1999; 9(4):285-292.
7. Foley J. Surgical Removal of Supernumerary Teeth and the Fate of Incisor Eruption. *EJPD*, 2004; 5(1):35-40.
8. Di Biase DD. Midline Supernumeraries and Eruption of the Maxillary Central Incisor. *Transactions of the BSSO*, 1969; 83-88.
9. Bergstrom K. An Orthopantomographic Study of Hypodontia, Supernumeraries and Other Anomalies in School Children between the Ages of 8-9 Years: an Epidemiologic Study. *Swed Dent J*, 1977; 1: 145-157.
10. Von Arx T. Anterior Maxillary Supernumerary Teeth: A Clinical and Radiographic Study. *Aust Dent J*, 1992; 37(3):189-95.
11. Kobayashi H, Taghuchi Y, Noda T. Eruption Disturbances of Maxillary Permanent Central Incisors Associated With Anomalous Adjacent Permanent Lateral Incisors. *Int J Paediatr Dent*, 1999;9(4):277-284.
12. Boon LC, Esa R. Impeded Eruption of a Maxillary Incisor by a Denticle and a Cyst. *ASDC J Dent. Child*, 1991; 58(4): 335-336.
13. Profitt WR, Fields HW, Ackerman JL, Sinclair PM, Thomas, PM, Tulloch JFC. 1993. *Contemporary Orthodontics* 2nd edition, Mosby.
14. Shelton JT, Owens BM, Schuman NJ. Compound Odontome Associated With an Impacted Permanent Central Incisor. *J. Tenn Dent Assoc*. 1997; 77(4):41-8.
15. Stewart DJ. Dilacerated Unerupted Maxillary Central Incisors. *British Dental Journal*, 1978; 145: 229-233.
16. Jones JW, Hussain J. Management of the Unerupted Incisor. *Dental Update*, 1996; 36-39.
17. Di Biase DD. The Effects of Variations in Tooth Morphology and Position of Eruption. *Dental Practitioner*, 1971; 22: 95-108.

18. Mac Phee, CG. The Incidence of Erupted Supernumerary Teeth in Consecutive Series of 4000 School Children. *J British Dent.*1935; 58:59-60.
19. Moyers RE, Van der Linden. Standards of Human Occlusal Development. Centre for Human Growth and Development. 1976, University of Michigan.
20. Jacobs SG. Radiographic Localization of Unerupted Maxillary Anterior Teeth Using the Vertical Tube Shift Technique: The History and Application of the Method with Some Case Reports. *Am J Orthod Dentofacial Orthop*,1999; 116(4):415-423.
21. Brook, AH. Dental Anomalies of Number, Form and Size: Their Prevalence in British Schoolchildren. *J Int Assoc Dent Child*,1974; 5(2):37-53.
22. Isaacson KG, Thom AR. Guidelines for the Use of Radiographs in Clinical Orthodontics. British Orthodontic Society, 2001 London.
23. Armstrong C, Johnston C, Burden D, Stevenson M. Localising Ectopic Maxillary Canines – Horizontal or Vertical Parallax? *Eur J Orthod*, 2003; 25: 585 – 89.
24. K Horner, M Islam, L Flygare, K Tsiklakis, E Whaites. Basic Principles for Use of Dental Cone Beam Computed Tomography: Consensus Guidelines of the European Academy of Dental and Maxillofacial Radiology. *Dentomaxillofacial Radiology*, 2009; 38: 187-195.
25. W. De Vos J, Casselman GRJ, Swennen: Cone-Beam Computerized Tomography (CBCT) Imaging of the Oral and Maxillofacial Region: A Systematic Review of the Literature. *Int. J. Oral Maxillofac. Surg*, 2009; 38: 609–625.
26. JM Nervina. Cone Beam Computed Tomography Use in Orthodontics. *Australian Dental Journal*, 2012; 57: (1 Suppl): 95-102.
27. A Alqerban, R Jacobs, S Fieuws, G Willems. Comparison of Two Cone Beam Computed Tomographic Systems Versus Panoramic Imaging For Localization of Impacted Maxillary Canines And Detection of Root Resorption. *European Journal of Orthodontics*, 2011; 33:93–102.
28. Deng-gao Liu, Wan-lin Zhang, Zu-yan Zhang, DDS Yun tang Wu, Xu-chen Ma. Localization of Impacted Maxillary Canines and Observation of Adjacent Incisor Resorption with Cone-Beam Computed Tomography. *Oral Surg Oral Med Oral Pathol Oral Radiol Endod*, 2008 ;105:91-8.
29. Schulze D, Heiland M, Thurmann H, Adam G. Radiation Exposure During Midfacial Imaging Using 4- And 16-Slice Computed Tomography, Cone Beam Computed Tomography Systems And Conventional Radiography. *Dentomaxillofac Radiol*, 2004 ;33(2):83-6.
30. Ludlow JB, Davies-Ludlow LE, Brooks SL, Howerton WB. Dosimetry of 3 CBCT Devices for Oral and Maxillofacial Radiology: CB Mercuray, Newtom 3G and I-CAT. *Dentomaxillofac Radiol*, 2006; 35 (4):219-26.
31. Sedentext CT Project. Radiation Protection No 172: Cone Beam CT for Dental and Maxillofacial Radiology Evidence-based Guidelines, 2011: Available from: http://www.sedentext.eu/system/files/sedentext_project_provisional_guidelines.
32. Grover PS, and Lorton L. The Incidence of Unerupted Permanent Teeth and Related Clinical Cases. *Oral Surg Oral Med Oral Pathol*, 1985; 29:420-425.
33. Munns D. Unerupted Incisors. *BJO*,1981; 8(1):39-42.

34. Kajiyama K and Kai H. Esthetic Management of an Unerupted Maxillary Central Incisor with A Closed Eruption Technique. *Am J Orthod and Dentofacial Orthop*, 2000; 118:224- 28.
35. Mitchell L, Bennett TG. Supernumerary Teeth Causing Delayed Eruption – A Retrospective Study. *British Journal of Orthodontics*, 1992; 19:41-46.
36. Witsenburg B, Boering G. Eruption of Impacted Permanent Incisors after Removal of Supernumerary Teeth. *International Journal of Oral Surgery*, 1981; 10:423-431.
37. Bryan RA, Cole BO and Welbury RR. Retrospective Analysis of Factors Influencing the Eruption of Delayed Permanent Incisors after Removal of Supernumerary Tooth Removal. *Eur J Paediatr Dent*, 2005; 6:84-89.
38. Ashkenazi M, Greenberg BP, Chodik G, Rakocz M. Postoperative Prognosis of Unerupted Teeth After Removal of Supernumerary Teeth or Odontomas, *Am J Orthod and Dentofacial Orthop*, 2007 ;131(5):614-9.
39. Ayers E, Kennedy D, Wiebe C. Clinical Recommendations for Management of Mesiodens and Unerupted Permanent Maxillary Central Incisors. *Eur Arch Paediatr Dent*, 2014; 15(6):421-428.
40. Primosch R. Anterior Supernumerary Teeth - Assessment and Surgical Intervention in Children. *Pediatric Dent*, 1981(2): 204-215.
41. Mason C, Azam N, Holt RD, Rule DC. A Retrospective Study of Unerupted Maxillary Incisors Associated With Supernumerary Teeth. *Br J Oral Maxfac Surg*. 2000; 38(1):62-5.
42. D Smailience, A Sidlauskas, J Bucinskiene. Impaction of The Central Maxillary Incisor Associated With Supernumerary Teeth: Initial Position And Spontaneous Eruption Timing. *Stomatologija, Baltic Dental And Maxillofacial Journal*, 2006; 8:103-107.
43. Pavoni C, Franchi L, Laganà G, Baccetti T, Cozza P. Management of Impacted Incisors Following Surgery to Remove Obstacles to Eruption: A Prospective Clinical Trial. *Pediatr Dent*. 2013; 35(4):364-8.
44. Peedikayil Faizal C. Delayed Tooth Eruption. *e-Journal of Dentistry*, 2011; Vol 1 Issue 4.
45. Koch H, Schwartz O, Klausen B. Indications for Surgical Removal of Supernumerary Teeth in the Premaxilla. *Int J Oral Maxillofac Surg*, 1986; 15(3): 273- 281.
46. Leyland L, Batra P, Wong F, Llewelyn R. A Retrospective Evaluation of the Eruption of Impacted Permanent Incisors after Extraction of Supernumerary Teeth. *J Clin Pediatr Dent*. 2006; 30(3):225-31.
47. Baranwal H C, Verma PK, Dwivedi C D, Srivastava R. Dentigerous Cyst Associated With An Impacted Maxillary Mesiodens. *Eur J Gen Dent*, 2012;1:50-3.
48. Koca H, Esin A, Aycan K. Outcome of Dentigerous Cysts Treated With Marsupialization. *J Clin Pediatr Dent*, 2009; 34(2):165-8.
49. J.Z Tanki, T.A Naqash, A Gupta, R Singh, A Jamwal. Impacted Maxillary Incisors: Causes, Diagnosis and Management. *IOSR Journal of Dental and Medical Sciences*, 2013; (IOSR-JDMS) e-ISSN: 2279-0853, p-ISSN: 2279-0861. Volume 5, Issue 2 , 41-45.

50. Jena AK, Duggal R, Roychoudhury A, Parkash H. Orthodontic Assisted Tooth Eruption in a Dentigerous Cyst: A Case Report. *J Clin Pediatr Dent*, 2004; 29:33-35.
51. Zhu JF, Marcushamer M, King DL, Henry RJ. Supernumerary and Congenitally Absent Teeth: A Literature Review. *J Clin Pediatr Dent*, 1996; 20(2):87-95.
52. Omer, Rashied SM, Anthonappa, Robert PK, Nigel M. Determination of the Optimum Time for Surgical Removal of Unerupted Anterior Supernumerary Teeth. *Pediatric Dentistry*, 2010; 32(1):14-20,
53. NN. Lygidakis, K Chatzidimitriou N, Theologie-Lygidakis, NA. Lygidakis. Evaluation of a Treatment Protocol for Unerupted Maxillary Central Incisors: Retrospective Clinical Study of 46 Children. *European Academy of Paediatric Dentistry* November 2014.
54. Vanarsdall RL, Corn H. Soft Tissue Management of Labially Positioned Teeth. *AJO*,1977; 72:53-64.
55. Vermette ME. Uncovering Labially Impacted Teeth: Apically Positioned Flap and Closed-Eruption Techniques. *The Angle Orthodontist*,1995; 65(1):23-34.
56. Hunt NP. Direct Traction Applied To Unerupted Teeth Using The Acid Etched Technique. *BJO*,1977; 4(4): 211-212.
57. Ferguson JW. Direct Bonding To Unerupted Teeth Using Light-Cured Adhesive *BJO*,1995; 22(3):273-274.
58. McBride LJ. Traction – A Surgical/Orthodontic Procedure. *Am J Orthod*, 1979; 76(3): 287-299.
59. Oliver RG, Hardy P. Practical and Theoretical Aspects of a Method of Orthodontic Traction to Unerupted Teeth Illustrated By Three Cases. *British Journal of Orthodontics*,1986; 13: 229-236.
60. Nilesh V. Joshi. Periodontal Status Following Treatment of Impacted Maxillary Canines by Closed Eruption Technique: An Overview and Case Report. Compendium of Continuing Education in Dentistry, 2014; Vol35 :Issue 3.
61. Prof Adrian Becker. Trouble Shooting Impacted Teeth: What Is Close Eruption Surgical Exposure. Newsletters Archive Bulletin #13, 2012.
62. Koutzoqlou SI, Kostaki A. Effect of Surgical Exposure Technique, Age and Grade of Impaction on Ankylosis of an Impacted Canine and the Effect of Rapid Palatal Expansion on Eruption: A Prospective Clinical Study. *American Journal of Orthodontic Dentofacial Orthopaedic*, 2013; 143(3):342-52.
63. S.Chaushu, I. Brin, Y. Ben-Bassat, Y.Zilberman and A.Becker Periodontal Status Following Surgical –Orthodontic Alignment of Impacted Central Incisors with an Open – Eruption Technique. *European journal of Orthodontics*, 2003; 25: 579-584.
64. Cercadillo – Ibarguven, Gargallo – Albiol J, Abad - Sánchez D, Echeverría - Garcia JJ, Berini – Aytès L, Gay – Escoda C. Periodontal Health and Esthetic Results in Impacted Teeth Exposed by Apically Positioned Flap Technique. *Med Oral Pathology Oral Cir Bucal*, 2011; 16(1):89-94.

65. St J. Crean, B. Banu and H. Coonar. Modified Apically Repositioned Flap in The Treatment of Unerupted Maxillary Central Incisors. *Dental Update*, 2000; 27:137-139.
66. N Topouzelis, P Tsaousoglou, V Pisoka, L Zouloumis. Dilaceration of Maxillary Central Incisor: A Literature Review. *Dental Traumatology*, 2010; 26:427-433.
67. Kearns HP. Dilacerated Incisors and Congenitally Displaced Incisors: Three Case Reports. *Dent Update*, 1998 ;25(8):339-42.
68. Lin Tng-Tzen. Treatment of An Impacted Dilacerated Maxillary Central Incisor. *Am. J Orthod Dentofacial Orthop*, 1999;115:406-409.
69. Nashashibi, IA. Orthodontic Movement of A Palatally Displaced, Dilacerated, Unerupted Maxillary Central Incisor. *Journal of Pedodontics*, 1986; 11(1): 83-90.
70. Sandler PJ, Reed RT. Treatment of a Dilacerated Incisor. *Journal of Clinical Orthodontics*, 1989; 22:374-376.
71. McNamara T, Woolfe SN, McNamara CM. Orthodontic Management of A Dilacerated Maxillary Central Incisor with an Unusual Sequel. *J Clin Orthod*, 1998; 32:293-7.
72. Kuvvetli SS, Seymen F, Gencay K. Management of an Unerupted Dilacerated Maxillary Central Incisor: A Case Report. *Dent Traumatol*, 2007; 23(4): 257-61.
73. Asher C, Lewis DH. The Integration of Orthodontic and Restorative Procedures in Cases with Missing Maxillary Incisors. *Br Dent J*, 1986; 60(7):241-245.
74. Harrison JE, Bowden DE. The Orthodontic Restorative Interface: Restorative Procedures to Aid Orthodontic Treatment. *Br J Orthod*, 1992;19(2):143-152.
75. Bowden DE, Harrison JE. Missing Anterior Teeth: Treatment Options And Their Orthodontic Implications. *Dent Update*, 1994; 21(10),428-434.
76. Altun C, Cehreli Zc, Guven G, Acikel C. Traumatic Intrusion of Primary Teeth And Its Effects on The Permanent Succesors: A Clinical Follow Up Study. *Oral Surgery Oral Medicine Oral Pathology, Oral Radiology, Endodontic*, 2009; 107(4):493-8.
77. Campbell KM, Casas MJ, Kenny DJ. Ankylosis of Traumatized Permanent Incisors: Pathogenesis And Current Approaches To Diagnosis And Management. *Journal Canadian Dental Association*, 2005; 71(10):763-8.
78. Kristin LH, Lokesh S, Parul T. Eruption Disturbances of the Maxillary Incisors: A Literature Review. *J Clint Pediant Dent*, 2008; 32(3): 221-230.
79. Guidelines on Management of the Developing Dentition and Occlusion in Pediatric Dentistry. *American Academy of Pediatric Dentistry*.
80. Savarrio, L, McIntyre GD. To Open or To Close Space – That is The Missing Lateral Incisor Question. *Dent Update*, 2005; 32:16-25.
81. Zachrisson, BU. Improving Orthodontic Results in Cases With Maxillary Incisors Missing. *Am J Orthod*, 1978;73(3):274-289.
82. Sabri, R. Management of Missing Maxillary Lateral Incisors. *J Am Dent Assoc*, 1999; 130(1):80-84.

83. B. Thilander. Orthodontic Space Closure versus Implant Placement in Subjects with Missing Teeth. *Journal of Oral Rehabilitation*, 2008; 35:64-71.
84. Stefan, R and Bengt, M. The Congenitally Missing Upper Lateral Incisor. A Retrospective Study of Orthodontic Space Closure versus Restorative Treatment. *European Journal of Orthodontics*, 2000; 22: 697-710.
85. Denys D, Shahbazian M, Jacobs R, Laenen A, Wyatt J, Vinckier F, Willems G. Importance of Root Development in Autotransplantations: A Retrospective Study of 137 Teeth with a Follow-Up Period Varying From 1 Week to 14 Years. *Eur J Orthod*, 2013; 35(5):680-8.
86. Chung WC, Tu YK, Lin YH, Lu HK. Outcomes of Autotransplanted Teeth with Complete Root Formation: A Systematic Review and Meta-Analysis. *J Clin Periodontol*, 2014; 41(4):412-23.
87. T Nčenko, G Omerca, V Varinauskas, E Bramanti, F Signorino, and M Cicciù. Tooth Auto-Transplantation as an Alternative Treatment Option: A Literature Review. *Dental Research Journal*, 2013; 10(1).
88. Kvint S, Lindsten R, Magnusson A, Nilsson P, Bjerklin K. Autotransplantation of Teeth in 215 Patients. A Follow-Up Study. *Angle Orthod*, 2010; 80(3):446-51.
89. Kristerson, L. Autotransplantation of Human Premolars. *International Journal of Oral Surgery*, 1985; 14: 200-213.
90. Paulsen HU, Andreasen JO. Eruption of Premolars Subsequent To Autotransplantation. A Longitudinal Radiographic Study. *Eur J Orthod*, 1998; 20(1):45-55.
91. Lewis DH, Eldridge DJ. Orthodontic/ Restorative Interface. *Dent Update*, 1992; 19(5):195-196, 198-199.
92. José Alberto de Souza Freitas, Ana Lúcia cPompéia Fraga de Almeida. Rehabilitative Treatment of Cleft Lip And Palate: Experience of the Hospital for Rehabilitation of Craniofacial Anomalies/ University of São Paulo, Brazil (HRAC/ USP) – Part 4: Oral Rehabilitation. *Journal of Applied Oral Science*, 2013; 21(3): 284-292.
93. Thilander B, Odman J, Lekholm U. Orthodontic Aspects of the Use of Oral Implants in Adolescents: A 10 Year Follow-Up Study. *European Journal of Orthodontics*, 2001; 23:715-731.
94. Sullivan RM. Perspectives on Esthetics in Implant Dentistry. *Compend Contin Educ Dent*, 2001; 22(8):685-692.
95. Laney WR, Jemt T, Harris D, Henry PJ, Krogh PH, Polizzi G, Zarb GA, Herrmann I. Osseointegrated Implants For Single-Tooth Replacement: Progress Report From A Multicenter Prospective Study After 3 Years. *Int J Oral Maxillofac Implants*, 1994; 9(1):49-54.
96. Cooper L, Felton DA, Kugelberg CF, Ellner S, Chaffee N, Molina AL, Moriarty JD, Paquette D, Palmqvist U. A Multicenter 12-Month Evaluation of Single-Tooth Implants Restored 3 Weeks After 1-Stage Surgery. *Int J Oral Maxillofac Implants*, 2001; 16(2):182-192.

SEARCH STRATEGY

The following MESH terms or free text terms were used either singly or in combination, search was limit to English, human and 2006 to June 2015.

<p>Epidemiology</p> <ul style="list-style-type: none"> • Definition • Prevalence • Aetiology/etiology <p>Eruption</p> <ul style="list-style-type: none"> • Unerupted • Non-eruption • Missing/Absent hypodontia, congenital, developmental, agenesis • Dilacerated • Impacted • Obstruction – supernumeraries, odontome, cyst, other pathology • Trauma • Delayed eruption • Impacted teeth • Primary retention • Embedded teeth • Pseudoanodontia • Late eruption • Retarded eruption • Arrested eruption • Primary failure of eruption • Misplaced teeth • Displaced teeth • Impaired eruption • Depressed eruption • Non-eruption • Submerged teeth • Reinclusion/inclusion of teeth • Paradoxical eruption 	<p>Teeth</p> <ul style="list-style-type: none"> • Central Incisor • Upper Incisor • Maxillary incisors <p>Investigations</p> <ul style="list-style-type: none"> • Clinical examination : palpation, • Radiographic: plain/ Cone-Beam Computed Tomography • Interceptive/preventive <p>Management</p> <ul style="list-style-type: none"> • Surgical exposure • Traction • Transplantation • Expansion – Rapid Maxillary/palatal Expansion • Prosthetic replacement • Space management <p>Exclude :</p> <ul style="list-style-type: none"> • Cleft Lip and/or Palate • Syndromic patients
---	---

Appendix 2

CLINICAL QUESTIONS

The clinical questions addressed by these guidelines are:

Introduction

1. What is the definition of unerupted maxillary incisor?
2. What is the aetiology of unerupted maxillary incisor?
3. What are the prevalence/ incidence of unerupted maxillary incisor?
4. What is the implication of unerupted maxillary incisors to occlusion, phonetics, aesthetics and psychological effect?

Diagnosis

5. What are the clinical presentations of unerupted maxillary incisor?
6. What are the investigations used to diagnose unerupted maxillary incisors?
7. What are the differences in the effectiveness between CT, CBCT and plain radiograph in determining the position of the unerupted incisor?
8. What radiographic information is required to recommend the best line of treatment for unerupted maxillary incisors?
9. What are the safety concerns of CT, CBCT and plain radiograph?

Preventive and early interceptive measures

10. When is the suitable age to intercept the problem?
11. What are the interceptive treatment options?

Management

12. What is the general principle of management of unerupted maxillary incisors?
13. What are the treatment options available to treat unerupted maxillary incisors?
14. What are the risk and benefit of early and late treatment?

ACKNOWLEDGEMENTS

The members of the development group of these guidelines would like to express their gratitude and appreciation to the following for their contributions:

- Panel of external reviewers
- Technical Advisory Committee for CPG for their valuable input and feedback
- Ms Zabidah bt Othman for processes involved in the publication
- All those who have contributed directly or indirectly to the development of the CPG

DISCLOSURE STATEMENT

The panel members had completed disclosure forms. None held shares in pharmaceutical firms or acts as consultants to such firms. (Details are available upon request from the CPG Secretariat)

SOURCE OF FUNDING

The development of the CPG on “MANAGEMENT OF UNERUPTED MAXILLARY INCISOR” was supported financially in its entirety by the Ministry of Health Malaysia and was developed without any involvement of the pharmaceutical industry.



Oral Health Technology Section
Oral Health Division
Ministry of Health Malaysia
Level 5, Block E10, Precinct 1
Federal Government Offices Centre
62590 Putrajaya, Malaysia

ISBN 978-967-0769-48-6



9 789670 769486